



## Shielding Fertility: Quercetin's Role in Battling Methomyl-Induced Pituitary-Testicular Axis Disruption

Ahmed I. El-Tokhy<sup>1\*</sup>, Abdel-Razik H. Abdel- Razik<sup>2</sup>, Mohamed Nabil<sup>3</sup>, Emad Ali Albadawi<sup>4</sup>, Eid Nassar Ali Musa<sup>4,5</sup> and Muayad S. Albadrani<sup>6</sup>

\* Corresponding author

Ahmed I. El-Tokhy



Received: 10/01/2025

Revised: 25/01/2025

Accepted: 26/01/2025

Published: 02/02/2025



©2025 by the authors.  
Licensee NVJAS, Egypt.  
This article is an open access  
article distributed under the  
terms and conditions of the  
Creative Commons  
Attribution (CC BY) license  
(<http://creativecommons.org/licenses/by/4.0/>).

<sup>1</sup>Plant Protection Department, Faculty of Agriculture, Beni-Suef University, Beni-Suef 62511, Egypt.

<sup>2</sup>Histology Department, Faculty of Veterinary Medicine, Beni-Suef University, Beni-Suef 62511, Egypt.

<sup>3</sup>Department of pharmacology, Faculty of Pharmacy, New Valley University, Kharga, Egypt

<sup>4</sup>Department of Basic Medical Sciences, College of Medicine, Taibah University, KSA

<sup>5</sup>Department of Anatomy and Embryology, Faculty of Medicine, Cairo University, Egypt

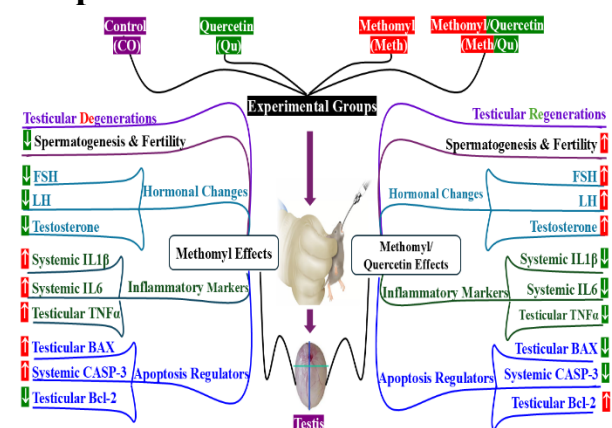
<sup>6</sup>Department of Family and Community Medicine and Medical Education, College of Medicine, Taibah University, Al-Madinah Al-Munawara 42353, Saudi Arabia

### Abstract

Pesticides play a crucial role in protecting crops and increasing yield, but unintended exposure can lead to adverse effects, especially on human health. High oxidative stress and inflammation can disrupt the hypothalamic-pituitary-gonadal axis, an important system for impacting gonadal activation, spermatogenesis, pubertal onset and fertility. This study aims to explore the testicular damage and changes in the hypothalamic-pituitary-testicular axis induced by subacute oral exposure to methomyl, as well as the potential protective effects of quercetin. The rats were divided into four groups: control (CO), methomyl-exposed (Meth), quercetin-treated (Qu), and methomyl plus quercetin (Meth/Qu). The methomyl group showed testicular apoptosis and decreased levels of pituitary and gonadal hormones, including follicle-stimulating hormone (FSH), luteinizing hormone (LH), and testosterone, along with elevated levels of pro-inflammatory cytokines (IL-1 $\beta$ , IL-6 and TNF- $\alpha$ ) and the pro-apoptotic marker (Caspase-3). Quercetin treatment alleviated these effects, improved hormone levels, and reversed methomyl-induced testicular damage. This study highlights the potential of quercetin, a nutritional anti-inflammatory substance, in mitigating methomyl-induced physiological disturbances.

**Keywords:** methomyl; quercetin; pituitary-testicular axis; apoptosis; inflammation

## Graphical Abstract



## Introduction

Pesticides are integral to contemporary agriculture, playing a crucial role in optimizing global food production (Selvam et al., 2013). Carbamates are a class of insecticides that are structurally and mechanistically like organophosphates. Methomyl, a widely used systemic insecticide, functions by inhibiting acetylcholinesterase activity in target pests (Fernandez-Alba et al., 2002). The World Health Organization (WHO), the European Commission (EC), and the Environmental Protection Agency (EPA) have classified methomyl as a hazardous substance, leading to its restricted use in many regions; nevertheless, its application as a pesticide remains extensive in certain areas (Jiang et al., 2020). Direct or indirect long-term exposure to methomyl can cause cytotoxicity, hepatotoxicity, neurotoxicity, and, most importantly, gonadal toxicity (Seleem 2019; He et al., 2022; Lu and Liu 2023).

The hypothalamic-pituitary-gonadal (HPG) axis is a highly complex neuroendocrine system in mammals that regulates reproduction through the precisely coordinated actions of pituitary gonadotropic hormones, including follicle-stimulating hormone (FSH) and luteinizing hormone (LH), which stimulate and regulate testicular testosterone production (Jeanne et al., 2024). Abnormal increases in protein markers associated with apoptosis and inflammation have been linked to impaired communication within the HPG axis (Taheri et

al., 2022). This disruption compromises gonadotropin secretion, testosterone synthesis, testicular steroidogenesis, and spermatogenesis, ultimately impacting male fertility and potentially leading to testicular degeneration (Khamis et al., 2020; Khamis et al., 2021; Ebokaiwe et al., 2022; van den Boogaard et al., 2022).

Quercetin, a naturally occurring plant bioflavonoid, has been the subject of extensive research over the past three decades (Shah et al., 2016). Numerous *in vitro* and *in vivo* studies have demonstrated a broad spectrum of biological activities associated with quercetin, including significant anti-inflammatory and antioxidant properties, alongside neuroprotective and immunomodulatory effects when administered at appropriate dosages (Zhou et al., 2023). The antioxidant mechanism of quercetin *in vivo* is primarily attributed to its concentration-dependent capacity to scavenge reactive oxygen species (ROS), modulate glutathione (GSH) levels, influence signal transduction pathways, and modulate enzyme activities (Boots et al., 2008). The anti-inflammatory and antioxidant properties of quercetin suggest a potential role in the prevention and treatment of pesticide-induced toxicities (Yang et al., 2020).

The study's objectives were to examine the inflammatory and apoptotic effects of subacute exposure of male rats to methomyl and its potential effect on the pituitary testicular regulatory axis. Additionally, to evaluate quercetin's possible protective effects against methomyl's inflammatory-apoptotic axis and its ability to mitigate the pituitary-testicular regulatory axis disruptions.

## Materials and methods

### Insecticides and chemicals

Methomyl (Goldben® 90% SP, insecticide), was obtained from Shoura Chemicals Company, Cairo, Egypt; Quercetin dihydrate 98 %, was sourced from HiMedia Laboratories Private Limited, Maharashtra, India; All other chemicals were analytical grade

and procured from Sisco Research Laboratories Pvt. Ltd. Maharashtra, India. Afia corn oil for safe and healthy use was purchased from Savola Group.

### Experimental animals

Male Sprague-Dawley (SD) rats, 2–3 weeks old and weighing  $49 \pm 15$  g, were purchased from Misr University for Science and Technology, Cairo, Egypt. The animals were housed in standard polypropylene cages under controlled environmental conditions (room temperature:  $24 \pm 2$  °C, humidity:  $40 \pm 20\%$ , and a 12-hour light/dark cycle) with unrestricted access to standard laboratory chow and water (ad libitum). At the start of the experiment, the rats were 8–9 weeks old and weighed  $160 \pm 20$  g.

### Ethical statement

The experimental design was approved by the New Valley Research Ethics Committee (NV-REC), New Valley university, Egypt, (approval number: NVREC 03/3/1-2024/9). All animal handling and experimental procedures complied with international guidelines for the care and use of laboratory animals.

### Experimental design

Twenty adult male (Sprague-Dawley) rats aged 8–9 weeks; weighing  $160 \text{ g} \pm 20 \text{ g}$  were randomly assigned into four groups ( $n = 5$  in each group) with approximately matched body weight. All groups received a standard chow diet and daily 0.5 ml corn oil by oral gavage for 28 consecutive days. Group 1 (CO): control rats that received standard chow diet and corn oil without any additives., Group 2 (Meth): rats that received 0.34 mg/kg b.w. (1/100 LD<sub>50</sub>) methomyl, dissolved in the corn oil., Group 3 (Qu): rats that received 50 mg/kg b.w. quercetin, dissolved in the corn oil., Group 4 (Meth/Qu): rats that received methomyl followed by quercetin after 2-hour interval with the mentioned doses dissolved in the corn oil. Our study selected a dose of 50 mg/kg of quercetin, in preference to 25 mg/kg doses and 100 mg/kg doses, based on the results of Uylaş et al. (2016) comparison of the three

concentrations (Uylaş et al., 2018). The animals were observed daily and weighed weekly for the duration of experimental.

### Blood and Tissue sampling

At the end of the 28-day dosing period, animals were anesthetized with an intraperitoneal injection of thiopental sodium (50 mg/kg). Firstly, blood was drawn from the orbital plexus via puncture and centrifuged at 4000 rpm for 15 minutes at 4 °C using a refrigerated centrifuge (BKC-TH21RM, Biobase®, Jinan, Shandong, China) to separate the serum, which was subsequently stored at -20 °C. Following blood collection, rats were euthanized by decapitation. The testicles of each animal were rapidly excised, rinsed in ice-cold 0.1 M phosphate-buffered saline (PBS, pH 7.4) to remove excess blood, and then fixed by immersion in 10% formalin for subsequent histopathological analysis.

### Determination of testosterone, gonadotrophic hormones, apoptotic, and inflammatory markers in serum blood.

Serum testosterone and LH levels were measured using rat ELISA kits supplied by CUSABIO, Wuhan, Hubei, China (Catalogue number: CSB-E05100r and CSB-E12654r, respectively); Serum FSH level was measured using rat ELISA kit supplied by Fine Test Biotech, Wuhan, Hubei, China (Catalogue number: ER0960); Serum Caspase 3 level was measured using rat ELISA kit supplied by Bioassay Technology Laboratory, Shanghai, China (Catalogue number: E1648Ra); Serum Interleukin 1 Beta (IL-1 $\beta$ ), Interleukin 6 (IL-6), and Tumor Necrosis Factor Alpha (TNF- $\alpha$ ) levels were measured using rat ELISA kits supplied by Elabscience, Houston, Texas, USA (Catalogue number: E-EL-R0012, E-EL-R0015, and E-EL-R0019, respectively). The manufacturer's instructions were adhered to throughout the procedures.

### Histopathological studies

The formalin-fixed testicular samples were washed in saline 0.09% NaCl, dehydrated by using ascending concentrations of ethyl

alcohol, then cleared in 2 changes of xylene, impregnated well in soft paraffin, and embedded and blocked in hard paraffin. By using of rotatory LEICA microtome, the obtained tissue blocks were cut in thickness 4–6  $\mu$ m, then fixed on clean and dry glass slides. Hematoxylin and eosin as a general histopathological stain were used to test the acquired slides. Histopathological examination was performed using a light microscope (LEICA, Heerbrugg, Switzerland) equipped with a DFC290 HD system digital camera, at 10x, 20x, and 40x magnification (Bancroft and Gamble 2008). Testicular damage was recorded according to the following scale: 0 indicates no change, 1 indicates 25% tissue damage, 2 indicates 26–50% tissue damage, 3 indicates 51–75% tissue damage, and 4 indicates 76–100% tissue damage (Gibson-Corley et al., 2013).

#### Immunohistochemical studies

Mouse monoclonal antibodies (Santa Cruz Biotechnology, CA, USA) were used in immunohistochemical staining for Bcl-2, BAX, and testosterone using the avidin-biotin peroxidase method. All markers' immunostaining showed up as brown cytoplasmic granules. After being cleaned with distilled water, the slides were counterstained with Harris hematoxylin (Jackson & Blythe, 2008), and ImageJ software (Microsoft Company) was used to determine the color density. Images were taken using a light microscope equipped with a 40x objective lens and a LEICA DFC290 HD digital camera (Bancroft and Gamble, 2013).

#### Statistical analysis

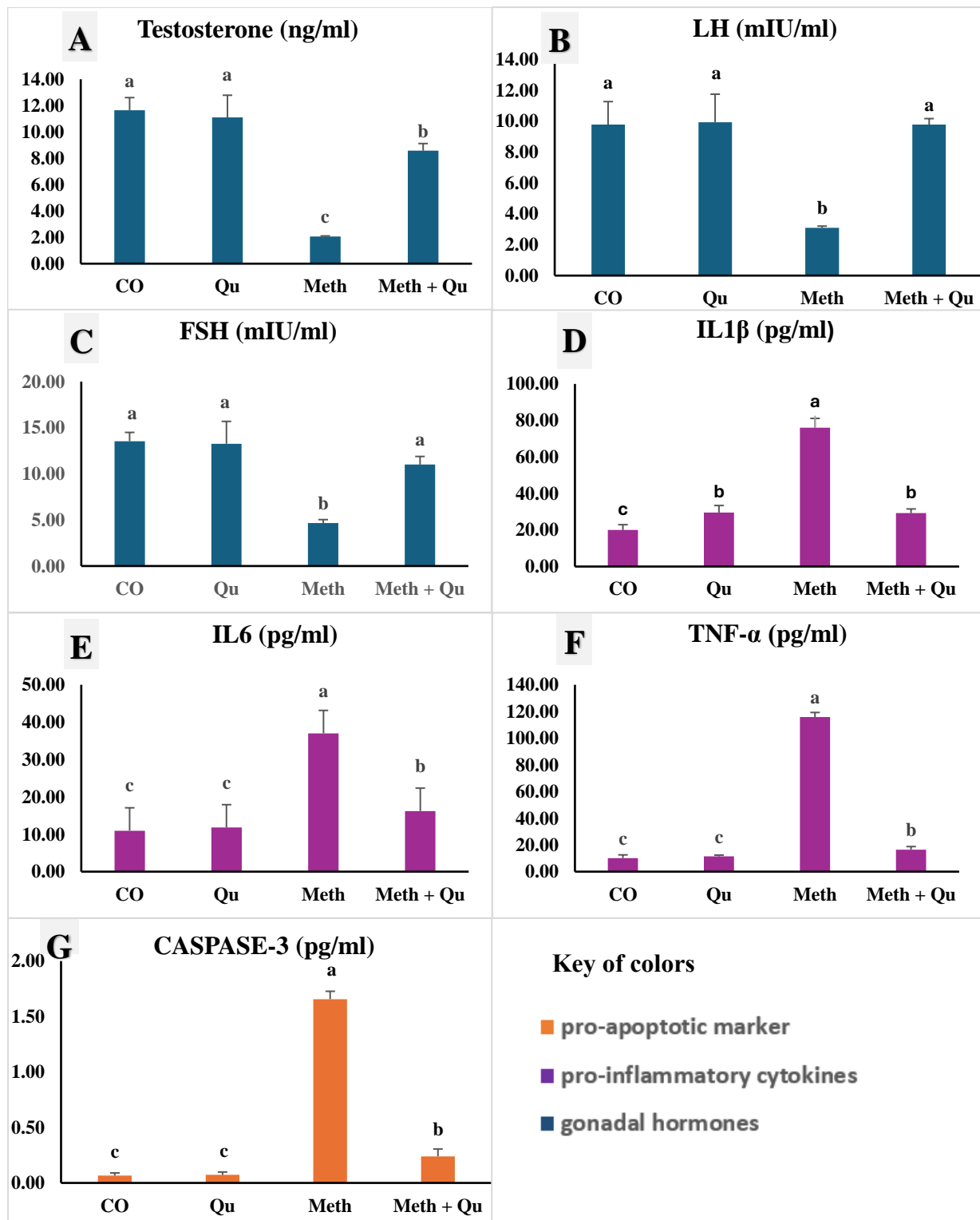
Data are presented as the mean  $\pm$  standard deviation. A P-value of  $< 0.05$  was considered statistically significant. Differences among the control and treatment groups were analyzed using one-way ANOVA, followed by the Duncan procedure for the multiple comparisons test. All analyses were performed using SPSS software (Version 22).

## Results

### Effects of methomyl, quercetin, and methomyl/quercetin combination on testosterone, gonadotrophic hormones, inflammatory, and apoptotic markers in serum by ELISA

As shown in Figure 1, methomyl administration significantly decreased testosterone by 5.7-fold ( $2.05 \pm 0.05$  vs.  $11.65 \pm 0.95$  ng/ml) (Fig. 1A), LH by 3-fold ( $3.10 \pm 0.11$  vs.  $9.78 \pm 1.48$  mIU/ml) (Fig. 1B), and FSH by 3-fold ( $4.65 \pm 0.38$  vs.  $13.54 \pm 0.94$  mIU/ml) (Fig. 1C), compared with the control group ( $P < 0.05$ ). Quercetin coadministration with methomyl markedly ameliorates the diminished testosterone levels by 4.2-fold ( $8.57 \pm 0.54$  vs.  $2.05 \pm 0.05$  ng/ml), LH by 3.2-fold ( $9.78 \pm 0.39$  vs.  $3.10 \pm 0.11$  mIU/ml), and FSH by 2.9-fold ( $11.0 \pm 0.87$  vs.  $4.65 \pm 0.38$  mIU/ml) compared to the methomyl group ( $p < 0.05$ ). No significant changes appeared in the serum levels of testosterone, LH, or FSH in the control rats compared to rats who received quercetin.

The administration of methomyl significantly elevated the serum levels of the inflammatory IL-1 $\beta$  by 3.8-fold ( $76.03 \pm 5.08$  vs.  $19.99 \pm 2.92$  pg/ml) (Fig. 1D), IL-6 by 3.4-fold ( $37.02 \pm 2.75$  vs.  $10.97 \pm 1.38$  pg/ml) (Fig. 1E), and TNF- $\alpha$  by 11.4-fold ( $115.78 \pm 3.46$  vs.  $10.18 \pm 2.39$  pg/ml) (Fig. 1F) compared with the control group ( $P < 0.05$ ). Quercetin coadministration with methomyl markedly lowered the elevated IL-1 $\beta$  levels by 2.6-fold ( $29.22 \pm 2.31$  vs.  $76.03 \pm 5.08$  pg/ml), IL6 by 3.4-fold ( $16.23 \pm 2.58$  vs.  $37.02 \pm 2.75$  pg/ml), and TNF- $\alpha$  by 7-fold ( $16.47 \pm 2.35$  vs.  $115.78 \pm 3.46$  pg/ml) compared to the methomyl group ( $p < 0.05$ ). No significant changes appeared in the serum levels of the inflammatory IL-6 and TNF- $\alpha$  in the control rats compared to rats who received quercetin. Rats received quercetin showed significantly higher serum levels of IL-1 $\beta$  compared to their control ( $29.57 \pm 3.83$  vs.  $19.99 \pm 2.92$  pg/ml) but did not markedly differ from that of methomyl + quercetin group rats.



**Figure (1):** Effect of methomyl, with or without quercetin, on testosterone (A), LH (B), FSH (C), IL-1β (D), IL-6 (E), TNF-α (F), and caspase 3 (G). Control group (CO): rats received a standard diet and drink; quercetin (Qu), rats received 50 mg/kg b.w.; methomyl (Meth), rats received 0.34 mg/kg b.w.; methomyl and quercetin (Meth/Qu), rats received 50 mg/kg b.w. Qu followed by 0.34 mg/kg b.w. Meth. All groups received 0.5 ml corn oil by oral gavage, a standard diet, and drink for 28 consecutive days, and treated groups received the tested compounds dissolved in the corn oil during the same period. Data are presented as mean ± S.D. (n = 6). Statistical analysis was performed using one-way ANOVA. Means followed by the same letters are not significantly different at 5%, according to Duncan's multiple range test.

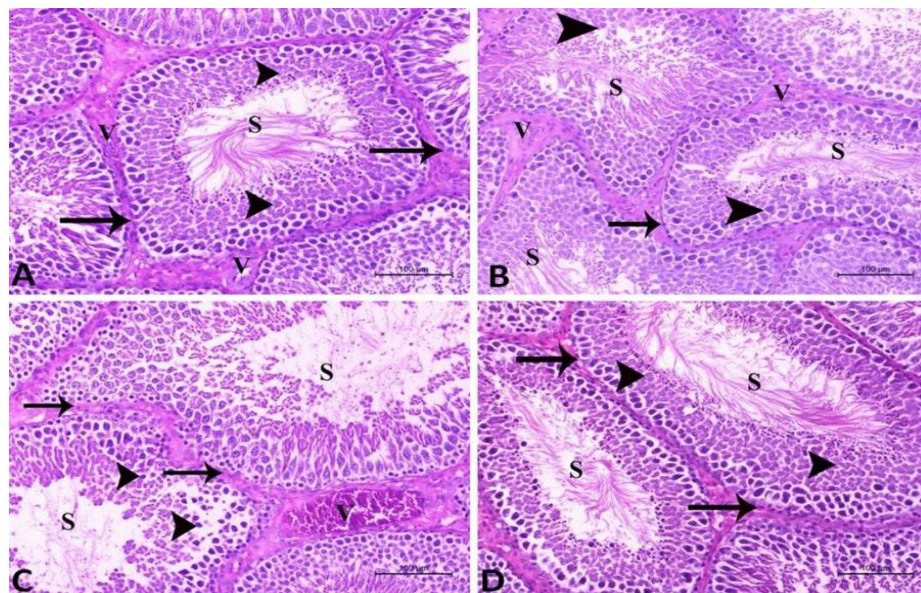


Methomyl administration dramatically elevated serum levels of apoptotic CASPASE-3 by 23.7-fold ( $0.66 \pm 0.07$  vs.  $0.07 \pm 0.02$  ng/ml) (Fig. 1G) while coadministration of quercetin with methomyl significantly reduced this elevation by 7-fold ( $0.24 \pm 0.07$  vs.  $1.66 \pm 0.07$  pg/ml) compared to methomyl group without significant difference with their control rats.

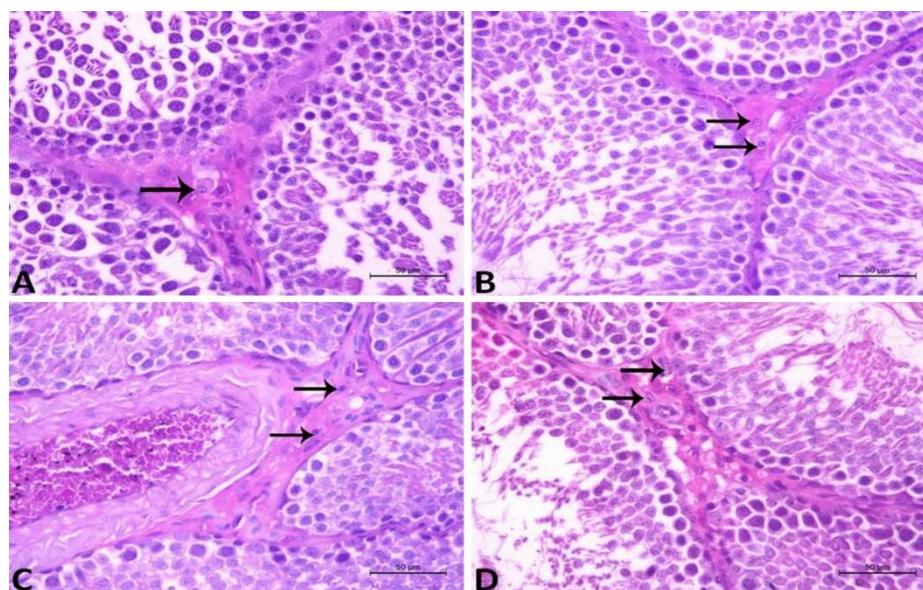
#### Effect of Quercetin on methomyl-induced histopathological changes on testis.

The findings of histopathology in examined groups revealed that in both control-negative and antioxidant groups, normal testicular tissue contains seminiferous tubules with normal and thin basal lamina. These tubules are lined with highly proliferative normal spermatogenic series containing in their lumen huge amounts of spermatids and spermatozoa (Fig. 2 [A & B]). The interstitial tissue contains clusters of

highly active and proliferative interstitial Leydig's cells around normal blood vessels (Fig. 3 [A & B]). On the other hand, the methomyl group shows testicular tissue with seminiferous tubules enclosed by thick basal lamina. The tubules are lined with degenerated and apoptotic spermatogenic cells containing in their lumen very few spermatids and spermatozoa (Fig. 2 [C]). The interstitial tissue contained very few and less active Leydig's cells around congested blood vessels (Fig. 3 [C]). By using Quercetin, antioxidants ameliorate the structure and function of the testicular tissue, represented by normal tubules with normal basal lamina and normal spermatogenic series, as well as considerable amounts of spermatids and spermatozoa in its lumen (Fig. 2 [D]). On the same level, the interstitial tissue accepts its normal continuant of interstitial Leydig's cells and regains its activity (Fig. 3 [D]).



**Figure (2):** A histopathological plate of testicular tissue in adult male rats showed: **A): CO group** with normal tubules (S), surrounded with basal lamina (arrow), normal spermatogenic series (arrowhead), and spermatozoa. The interstitial contains normal blood vessels (V). **B): Qu group** showed normal tubules (S), normal basal membrane (arrow), and spermatogenic series (arrowhead) and spermatozoa. The interstitial tissue contains normal blood vessels (V). **C: Meth group** showing tubules (S) enclosed with thick basement lamina (arrow) and lined by spermatogenic series with degenerative changes accompanied with few spermatids and spermatozoa. Note: the interstitial tissue contained congested blood vessels (V). **D): Meth + Qu group** showing normal tubules (S) with normal basal lamina (arrow) lined by normal spermatogenic series as well as spermatids and sperm.



**Figure (3):** A higher magnification of the interstitial Leydig's cells in testicular tissue of adult male rats showing **A): CO group** showed clusters of highly active and proliferative Leydig's cells (arrow). **B): Qu group** showed clusters of highly active and proliferative Leydig's cells (arrow). **C): Meth group** showing few less active Leydig's cells (arrow). **D): Meth + Qu group** showing clusters of highly active and proliferative Leydig's cells (arrow).

**Table (1): Lesions scoring of Testicle in the tested groups**

| Pathophysiological changes        | Treatment |    |      |           |
|-----------------------------------|-----------|----|------|-----------|
|                                   | Co        | Qu | Meth | Meth + Qu |
| Spermatogenic series degeneration | 0         | 0  | 2    | 0         |
| Sperms Depletion                  | 0         | 0  | 2    | 0         |
| Activity of Leydig's cells        | 4         | 4  | 2    | 3         |
| Thickening of the basal membrane  | 0         | 0  | 3    | 0         |
| Congestion of testicular vessels  | 0         | 0  | 3    | 1         |
| Edema of the interstitial tissue  | 0         | 0  | 1    | 0         |

Scoring of testicular tissue damage was recorded in degrees: 0 = no change; 1 ≤ 25% tissue damage; 2 = 26–50% tissue damage; 3 = 51–75% tissue damage; 4 = 76–100% tissue damage. Control group (CO): rats received a standard diet and drink; quercetin (Qu), rats received 50 mg/kg b.w.; methomyl (Meth), rats received 0.34 mg/kg b.w.; methomyl and quercetin (Meth/Qu): rats received 50 mg/kg b.w. Qu followed by 0.34 mg/kg b.w. Meth.

### Effect of Quercetin on Methomyl-induced immunohistochemical changes on testis.

The immunohistochemical findings in the primitive spermatogonia cells, primary spermatocytes, secondary spermatocytes, and interstitial Leydig's cells in control and quercetin groups showed high antiapoptotic Bcl-2 expression, Fig.4 (A&B) in percentages of 45.2% and 44.5%, respectively, Fig.7, and low expression of the apoptotic BAX, Fig.5 (A&B), in percentages of 4% and 4.8 %, Fig.7. The interstitial Leydig's cells in control

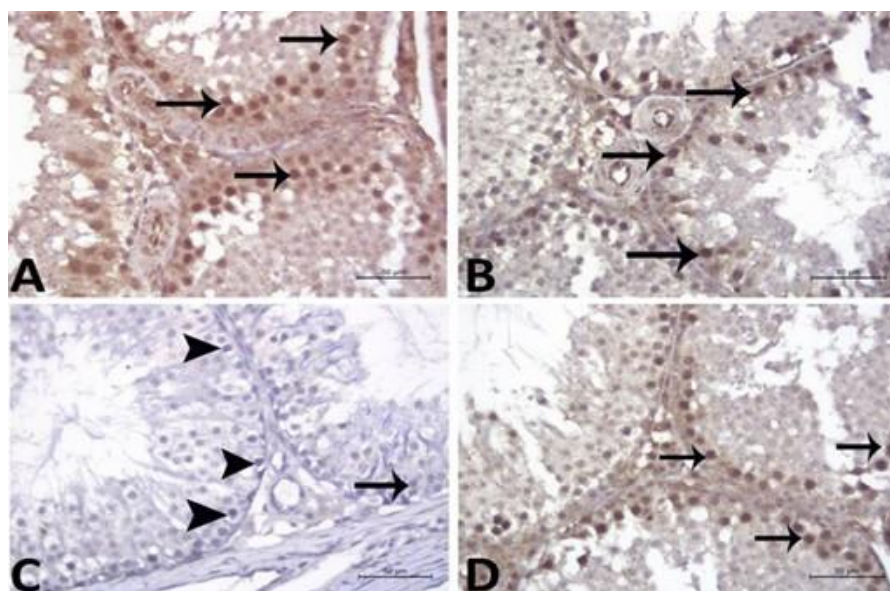
and quercetin groups markedly expressed testosterone receptors, Fig.6 (A&B), in 6.5% and 6.6% percentages, Fig.7. The methomyl-treated primitive spermatogonia cells, primary spermatocytes, secondary spermatocytes, and interstitial Leydig's cells showed low expression of Bcl-2, Fig.4 (C), in a percentage of 8%, Fig.7, and high expression of BAX, Fig.5 (C), in the percentage of 32.5% Fig. 7. The interstitial Leydig's cells expressed very few reactions of



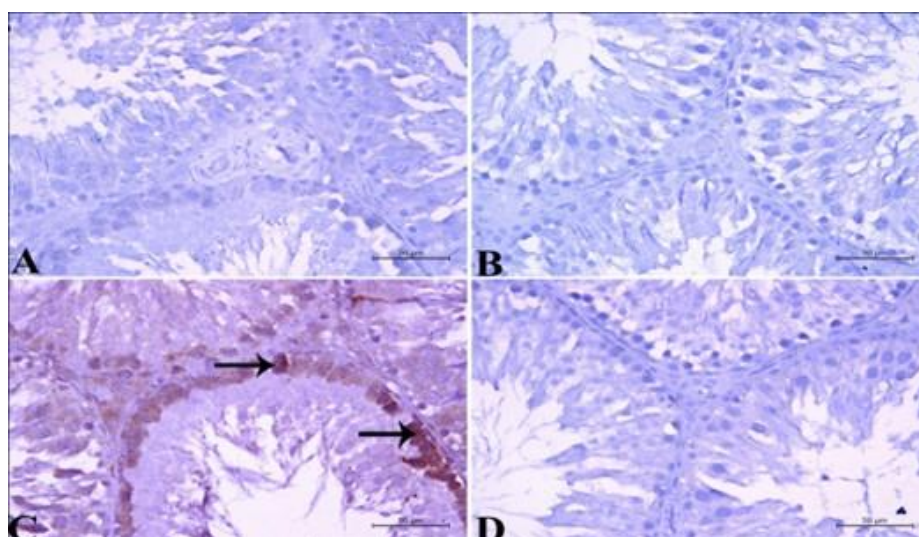
testosterone Fig.6 (C), in a percentage of 1.2%, Fig.7.

Quercetin positively impacted the expression of Bcl-2, Fig.4 (D), by a percentage increase of 42.8%, Fig.7, and lowered the expression of BAX, Fig.5 (D), by

a percentage of 6.2%, Fig.6. On the same level, the interstitial Leydig's cells regain their activity in the production of testosterone by increasing its expression Fig.6 (D) in a percentage of 5.9% Fig.7.

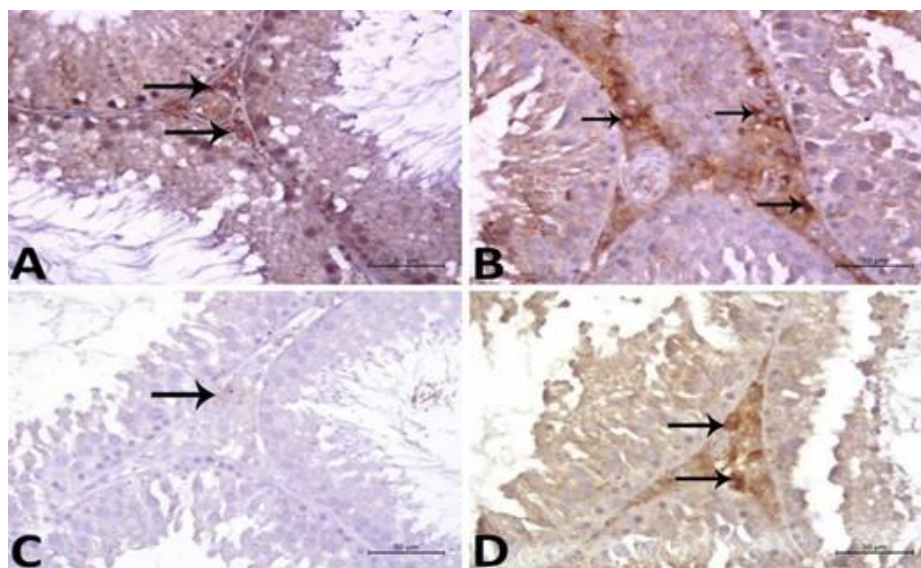


**Figure (4):** An immunohistochemical plate of testicular tissue in adult male rats showing **A): CO group** show strong reaction in the highly proliferative spermatogenic series (arrow). **B): Qu group** showed strong reaction in the highly proliferative spermatogenic series (arrow). **C): Meth group** showing negative reaction in the spermatogenic series (arrowhead) on the other hand very few cells showed very faint reaction in the spermatogenic cells (arrow). **D): Meth + Qu group** showed strong reaction in the highly proliferative spermatogenic cells (arrow). (Bc immunoreaction X400)

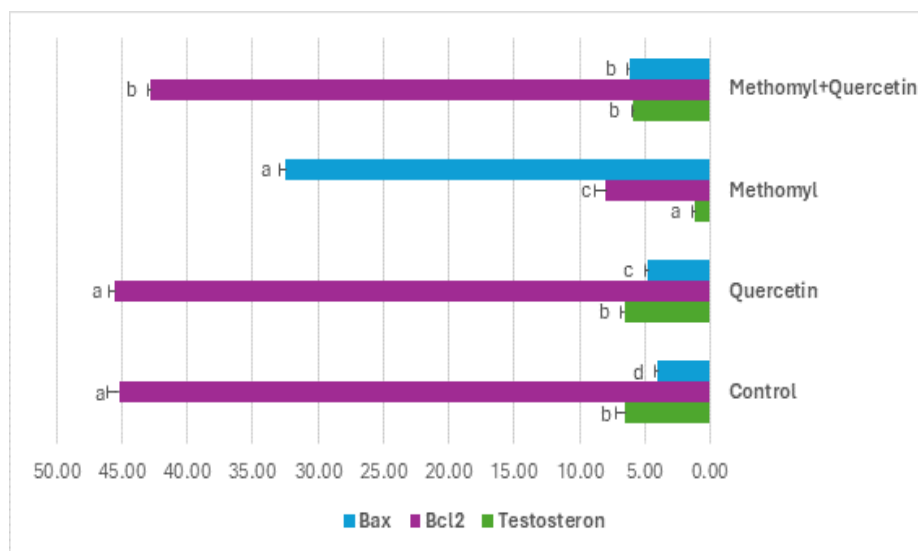


**Figure (5):** An immunohistochemical plate of testicular tissue in adult male rats showing **A): CO group** showed negative reaction spermatogenic series (arrow). **B): Qu group** showed negative reaction in spermatogenic series (arrow). **C): Meth group** showing strong reaction in the spermatogenic series (arrow). **D): Meth + Qu group** showed negative reaction in the spermatogenic cells (arrow). (Bax immunoreaction X400)





**Figure (6):** The interstitial Leydig's cells in testicular tissue of adult male rats showing **A): control negative group** showed strongly reacted Leydig's cells (dark brown granules) (arrow). **B): Quercetin group** showed strongly reacted Leydig's cells (dark brown granules) (arrow). **C: Methomyl treated group** showing faintly reacted Leydig's cells (very few faint brown granules) (arrow). **D): Methomyl + quercetin treated group** showing strongly reacted Leydig's cells (dark brown granules) (arrow). (**Testosterone immunoreaction X400**).



**Figure (7):** Percentages represent the % of positively stained cells including primitive spermatogonia, primary spermatocytes, secondary spermatocytes, and interstitial Leydig's cells identified by immunohistochemical staining cells in treated groups. Statistical analysis was performed using one-way ANOVA. Means followed by the same letters are not significantly different at 5%, according to Duncan's multiple range test.

## Discussion

Methomyl and other carbamate insecticides have been widely used to manage agricultural pests, which has led to their frequent ecological presence. It is extremely toxic in humans when taken orally, moderately toxic upon inhalation, and mildly toxic with topical application (Van Scoy et al., 2013). This study investigated the testicular toxicity of orally administered methomyl and its effects on the pituitary-testicular axis in a rat model. To our knowledge, this study is the first to examine quercetin's possible ameliorative effect on methomyl's pituitary-testicular axis disruptions. Our results demonstrated that quercetin administration (50 mg/kg b.w., dissolved in corn oil) significantly restored the levels of pituitary-testicular axis hormones and improved testicular histology. Our findings not only showed quercetin's testicular protective effects but also outlined the mechanisms involved in this effect. The following findings were obtained: (1) Quercetin ameliorated the structural derangements of the testicular tissue. (2) It reduced systemic and testicular apoptosis regulators and improved testicular anti-apoptotic signaling. (3) Additionally, we demonstrated quercetin's anti-inflammatory properties and the modulatory action of quercetin on the FSH, LH, and testosterone as a contributing mechanism regarding testicular spermatogenesis.

Reactive oxygen species (ROS) and reactive nitrogen species (RNS) are by-products of cellular respiration, and their primary physiological function is to regulate cellular homeostasis through the mediation of pathogen defense, redox signaling, and protein folding (Navarro-Yepes et al., 2014). However, excessive levels of these reactive species can interact with cellular lipids, carbohydrates, amino acids, proteins, and nucleic acids, resulting in metabolic abnormalities that are extremely harmful to cell survival (Franklin 2011). Testicular germ cells are created clonally in the seminiferous epithelium by numerous mitotic divisions until they become haploid spermatids, which structurally differentiate into spermatozoa

(Dacheux and Dacheux 2014). Trace amounts of spermatozoa endogenous ROS are importantly required for the inhibition of tyrosine phosphatase activity causing large production of cAMP and phosphorylation of target proteins involved in the maturation and daily production of spermatozoa to develop the capacity to fertilize the oocyte (Chen et al., 2013). The plasma membrane of spermatozoa contains a significant quantity of polyunsaturated fatty acids (PUFA), plus their lack of critical cytoplasmic antioxidant enzymes renders them very vulnerable to oxidative damage by ROS and hydrogen peroxide (Ommati et al., 2013). Lipid peroxidation was brought on by pesticides belonging to the carbamate and their metabolism byproducts suggested that one of their molecular toxicities is lipid peroxidation, where the biological membranes PUFA undergo oxidative degradation, alter their structure and function, reduce their fluidity, and inactivate many of the enzymes that are attached to them (El-Demerdash et al., 2013).

Methomyl was reported to produce significant depletion in testicular reduced GSH, superoxide dismutase (SOD), glutathione reductase, catalase, and glutathione-S-transferase, whilst oxidized glutathione was markedly elevated (Heikal et al., 2014; Heikal 2015; Meng et al., 2021; Li et al., 2024; Mowafy et al., 2024). The pathophysiology of many inflammatory illnesses is linked to the activation of redox-sensitive transcription factors that transcribe a variety of inflammatory cytokines, chemokines, and other inflammatory markers (He et al., 2022). The elevated expressions of systemic pro-inflammatory IL-1 $\beta$ , TNF- $\alpha$ , and IL-6 were reported to coincide with the elevation of testicular ROS levels and depletion of antioxidant machinery (Okur et al., 2018; Mohamed et al., 2020). Parallel to these findings, the present study showed that methomyl provoked a more than threefold increase in the systemic IL-1 $\beta$  and IL-6, while the TNF- $\alpha$  tremendously increased by more than elevenfold. The prolonged cellular exposure to oxidative and inflammatory stress

is associated with markedly elevated apoptotic BAX and caspase-3 expression (Heikal et al., 2014; He et al., 2022; Li et al., 2024) and a significant decrease in anti-apoptotic Bcl2 (Heikal et al., 2014; Heikal, 2015; Li et al., 2024). Our immunohistochemical investigation of the testicular apoptotic Bax expression showed its increase by eight times, accompanied by that anti-apoptotic Bcl-2 showed a fivefold decrease and a concurrent decline in testosterone expression simultaneously with immensely increased systemic apoptotic caspase3 by more than 23-fold upon exposure to oral methomyl.

Our study's histopathological investigation of oral methomyl effects on the testicular tissue reflects the failure of the testicular cells to survive and agrees with previous studies that demonstrated, like our study, a thickening of the basement membrane surrounding seminiferous tubules (Mahgoub and El-Medany 2001; Radad et al., 2009; Lu and Liu 2023), spermatogenic cell degeneration and apoptosis (Mahgoub and El-Medany 2001), and a reduced number of spermatids and sperms beside a small number of less active Leydig's cells surrounding clogged blood vessels (Mahgoub and El-Medany 2001; Sakr et al., 2018). This testicular apoptosis tendency obviously resulted from the methomyl-induced oxidative and inflammatory stress in line with the fact that the spermatozoa plasma membrane is rich in PUFA which makes it particularly susceptible to damage by ROS mainly lipid peroxidation (Aitken et al., 2016). The level of testicular testosterone expression in this study drops to almost one-sixth of the normal level, and this makes sense with our observed histopathological testicular degenerative changes and systemic inflammation. These data are in line with studies reporting the incidence of methomyl testicular degenerative changes and sperm cell abnormalities with low levels of serum testosterone and fertility index (Shalaby et al., 2010; Heikal et al., 2014; Lu and Liu 2023; Mowafy et al., 2024).

Since the development and regulation of the reproductive systems are significantly influenced by the hypothalamic-pituitary-gonadal axis (Radad et al., 2009; Ye and Liu 2019), which is significantly impacted by systemic inflammation (Tsukamura 2022). Our results demonstrate that oral methomyl administration in rats showed that both serum LH and FSH significantly decreased to one-third of the control rats' level concomitantly with a tremendous elevation in their serum IL-1 $\beta$ , IL-6, and TNF- $\alpha$ . Other studies have reported lower testosterone, LH, and FSH levels following oral exposure for 60 days to the carbamate carbosulfan (Prakash and David 2020), while carbaryl increased LH and FSH with a decrease in testosterone (Jain et al., 2010; Ichimura et al., 2013; Saha et al., 2022). Methomyl administration in the present study for 28 days at a dosage of 0.34 mg/kg b.w., significantly lowered FSH, LH, and testosterone while the study of Mahgoub and El-Medany, 2001 in which methomyl administered orally (17 mg/kg (-1) in saline) every day for two months showed a contrary direction where the level of testosterone significantly decreased, but the levels of FSH and LH greatly increased (Mahgoub and El-Medany 2001). This controversy could be attributed to the length of exposure and dosage of methomyl. These studies, like ours, examined oral exposure to insecticides, but the other routes of administration could also produce more controversial differences.

Quercetin showed a great inhibition specificity and high binding affinity towards several endogenous oxidative enzymes. Its phenolic and ketone groups' electron donation capability allows it to act as a free radical scavenger with a strong antioxidant effect (Olla et al., 2023; Yu et al., 2024). Other studies confirmed that quercetin effectively regulates the pro-inflammatory mediator and ROS signaling pathways, inhibiting their overexpression and ameliorating cytokine storm (Bin-Jaliah 2021; Xu et al., 2024), besides having an inhibitory effect on the apoptosis regulator Bax and caspase-3 (Bin-Jaliah 2021; Moghaddam et al., 2023) and elevating anti-apoptotic Bcl-2 expression



(Moghaddam et al., 2023). Quercetin's particularly testicular protective effect against various etiologies damage was reported to be mediated through its antioxidant properties (Bharti et al., 2014; Adedara et al., 2017; Nna et al., 2017), ability to lower pro-inflammatory IL6, IL1 $\beta$ , and TNF $\alpha$  levels (Tvrdá et al., 2022) and apoptosis regulators Bax and caspase-3 expressions (Bharti et al., 2014; Adedara et al., 2017; Nna et al., 2017; Tvrdá et al., 2022; Yu et al., 2024) besides substantial elevation of anti-apoptosis Bcl-2 (Bharti et al., 2014; Nna et al., 2017; Tvrdá et al., 2022), and ameliorating of degenerative changes (Adedara et al., 2017; Nna et al., 2017), reversal of induced decreases in LH, FSH, and testosterone reproductive hormones (Bharti et al., 2014; Adedara et al., 2017).

The effect of quercetin against testicular toxicity induced by methomyl has not been examined before, to our knowledge. Our study showed that oral administration of 50 mg/kg b.w. of quercetin, even with the coinciding administration of methomyl, tremendously ameliorates the systemic storm of IL-1 $\beta$ , IL6 and TNF- $\alpha$ . Concomitantly with a vast lowering in systemic apoptotic caspase-3 and testicular Bax levels and elevation of testicular Bcl-2 expression. This quercetin-mediated amelioration of the inflammation-apoptosis axis is supported by our histological findings, showing a significant reduction in testicular vessel congestion, interstitial tissue edema, and a restoration of the seminiferous tubule basement membrane thickness. The amelioration of testicular degeneration and inflammatory-apoptotic axis in the present study was apparently reflected in the levels of FSH, LH, and testosterone, which approximately normalized without significant differences from rats that were not exposed to oral methomyl.

## Conclusion

According to our research, quercetin's amelioration of the inflammatory-apoptotic axis may be able to reduce pesticide-induced testicular disruptions. Our study suggests the potential of quercetin, a bioflavonoid, as a prophylactic and therapeutic agent for mitigating methomyl-induced testicular

dysfunction. These findings represent a promising first step towards developing strategies to maintain fertility in the context of exposure to pesticides like methomyl. Even though quercetin's medicinal uses seem promising, thorough clinical research should be conducted before any future clinical applications are made.

## Conflicts of interest

There are no conflicts of interest.

## Funding statement

No specific grant from a public or private organization was obtained for this study.

## References

- Adedara, I. A., Subair, T. I., Ego, V. C., Oyediran, O., & Farombi, E. O. (2017). Chemoprotective role of quercetin in manganese-induced toxicity along the brain-pituitary-testicular axis in rats. *Chemico-Biological Interactions*, 263, 88–98.  
<https://doi.org/10.1016/j.cbi.2016.12.019>
- Aitken, R. J., Gibb, Z., Baker, M. A., Drevet, J., & Gharagozloo, P. (2016). Causes and consequences of oxidative stress in spermatozoa. *Reproduction, Fertility and Development*, 28(2), 1–10.  
<https://doi.org/10.1071/rd15325>
- Bancroft, J. D., & Gamble, M. (2013). *Theory and practice of histological techniques* (6th ed.). Churchill Livingstone, Elsevier.
- Bharti, S., Misro, M., & Rai, U. (2014). Quercetin supplementation restores testicular function and augments germ cell survival in the estrogenized rats. *Molecular and Cellular Endocrinology*, 383(1-2), 10–20.  
<https://doi.org/10.1016/j.mce.2013.11.021>
- Bin-Jaliah, I. (2021). Quercetin Inhibits ROS-p53-Bax-caspase-3 Axis of Apoptosis and Augments Gonadotropin and Testicular Hormones in Chronic Unpredictable Stress-Induced Testis Injury. *International Journal of Morphology*, 39(3).

- <http://dx.doi.org/10.4067/S0717-95022021000300839>
- Boots, A. W., Haenen, G. R., & Bast, A. (2008). Health effects of quercetin: From antioxidant to nutraceutical. *European Journal of Pharmacology*, 585(2-3), 325–337. <https://doi.org/10.1016/j.ejphar.2008.03.008>
- Chen, S.-j., Allam, J.-P., Duan, Y.-g., & Haidl, G. (2013). Influence of reactive oxygen species on human sperm functions and fertilizing capacity including therapeutical approaches. *Archives of Gynecology and Obstetrics*, 288, 191–199. <https://doi.org/10.1007/s00404-013-2801-4>
- Dacheux, J.-L., & Dacheux, F. (2014). New insights into epididymal function in relation to sperm maturation. *Reproduction*, 147(2), R27–R42. <https://doi.org/10.1530/REP-13-0420>
- Ebokaiwe, A. P., Obasi, D. O., Njoku, R. C., & Osawe, S. (2022). Cyclophosphamide-induced testicular oxidative-inflammatory injury is accompanied by altered immunosuppressive indoleamine 2, 3-dioxygenase in Wister rats: influence of dietary quercetin. *Andrologia*, 54(3), e14341. <https://doi.org/10.1111/and.14341>
- El-Demerdash, F., Dewar, Y., ElMazoudy, R. H., & Attia, A. A. (2013). Kidney antioxidant status, biochemical parameters and histopathological changes induced by methomyl in CD-1 mice. *Experimental and Toxicologic Pathology*, 65(6), 897–901. <https://doi.org/10.1016/j.etp.2013.01.002>
- Fernandez-Alba, A. R., Hernando, D., Agüera, A., Cáceres, J., & Malato, S. (2002). Toxicity assays: A way for evaluating AOPs efficiency. *Water Research*, 36(17), 4255–4262. [https://doi.org/10.1016/S0043-1354\(02\)00165-3](https://doi.org/10.1016/S0043-1354(02)00165-3)
- Franklin, J. L. (2011). Redox regulation of the intrinsic pathway in neuronal apoptosis. *Antioxidants & Redox Signaling*, 14(8), 1437–1448. <https://doi.org/10.1089/ars.2010.3596>
- Gibson-Corley, K. N., Olivier, A. K., & Meyerholz, D. K. (2013). Principles for valid histopathologic scoring in research. *Veterinary Pathology*, 50(6), 1007–1015. <https://doi.org/10.1177/0300985813485099>
- He, D., Xu, Y., Hou, L., Wang, J., Yang, S., Wang, Y., Zhang, S., Jin, Q., & Gao, Q. (2022). Toxic effects of methomyl on mouse oocytes and its possible mechanisms. *Zygote*, 30(3), 358–364. <https://doi.org/10.1017/S0967199421000782>
- Heikal, T. (2015). Antioxidant potentials of *Origanum majorana* leaves extract against reproductive toxicity and apoptosis-related gene expression resulted from methomyl exposure in male rat. *Planta Medica*, 81(16), PM\_13. <https://doi.org/10.1055/s-0035-1565390>
- Heikal, T. M., Mossa, A.-T. H., & Khalil, W. (2014). Protective effects of vitamin C against methomyl-induced injuries on the testicular antioxidant status and apoptosis-related gene expression in rat. *Journal of Environmental Analysis and Toxicology*, 5(2), 255–262.
- Hoizey, G., Canas, F., Binet, L., Kaltenbach, M. L., Jeunehomme, G., Bernard, M. H., & Lamiable, D. (2008). Thiodicarb and methomyl tissue distribution in a fatal multiple compounds poisoning. *Journal of Forensic Sciences*, 53(2), 499–502. <https://doi.org/10.1111/j.1556-4029.2008.00676.x>
- Ichimura, Y., Waguri, S., Sou, Y.-s., Kageyama, S., Hasegawa, J., Ishimura, R., Saito, T., Yang, Y., Kouno, T., & Fukutomi, T. (2013). Phosphorylation of p62 activates the Keap1-Nrf2 pathway during selective autophagy. *Molecular Cell*, 51(5), 618–631.

- <https://doi.org/10.1016/j.molcel.2013.08.003>
- Jackson, P., & Blythe, D. (2008). Immunohistochemical techniques. In J. D. Bancroft & M. Gamble (Eds.), *Theory and practice of histological techniques* (7th ed., pp. 381-426). Churchill Livingstone.
- Jain, A., Lamark, T., Sjøttem, E., Larsen, K. B., Awuh, J. A., Øvervatn, A., McMahon, M., Hayes, J. D., & Johansen, T. (2010). p62/SQSTM1 is a target gene for transcription factor NRF2 and creates a positive feedback loop by inducing antioxidant response element-driven gene transcription. *Journal of Biological Chemistry*, 285(29), 22576–22591. <https://doi.org/10.1074/jbc.M110.118976>
- Jeanne, F., Pilet, S., Klett, D., Combarrous, Y., Bernay, B., Dufour, S., Favrel, P., & Sourdain, P. (2024). Characterization of gonadotropins and their receptors in a chondrichthyan, *Scyliorhinus canicula*, fills a gap in the understanding of their coevolution. *General and Comparative Endocrinology*, 358, 114614. <https://doi.org/10.1016/j.ygcen.2024.114614>
- Jiang, W., Zhang, C., Gao, Q., Zhang, M., Qiu, J., Yan, X., & Hong, Q. (2020). Carbamate CN hydrolase gene *ameH* responsible for the detoxification step of methomyl degradation in *Aminobacter aminovorans* strain MDW-2. *Applied and Environmental Microbiology*, 87(1), e02005-20. <https://doi.org/10.1128/AEM.02005-20>
- Khamis, T., Abdelalim, A. F., Abdallah, S. H., Saeed, A. A., Edress, N. M., & Arisha, A. H. (2020). Early intervention with breast milk mesenchymal stem cells attenuates the development of diabetic-induced testicular dysfunction via hypothalamic Kisspeptin/Kiss1r-GnRH/GnIH system in male rats. *Biochimica et Biophysica Acta (BBA)-Molecular Basis of Disease*, 1866(1), 165577. <https://doi.org/10.1016/j.bbadis.2019.165577>
- Khamis, T., Abdelalim, A. F., Saeed, A. A., Edress, N. M., Nafea, A., Ebian, H. F., Algendy, R., Hendawy, D. M., Arisha, A. H., & Abdallah, S. H. (2021). Breast milk MSCs upregulated  $\beta$ -cells PDX1, Ngn3, and PCNA expression via remodeling ER stress/inflammatory/apoptotic signaling pathways in type 1 diabetic rats. *European Journal of Pharmacology*, 905, 174188. <https://doi.org/10.1016/j.ejphar.2021.174188>
- Li, M., Chen, X., Song, C., Xu, J., Fan, L., Qiu, L., Li, D., Xu, H., Meng, S., Mu, X., Xia, B., & Ling, J. (2024). Sub-Chronic Methomyl Exposure Induces Oxidative Stress and Inflammatory Responses in Zebrafish with Higher Female Susceptibility. *Antioxidants*, 13(7). <https://doi.org/10.3390/antiox13070871>
- Lu, M., & Liu, Y. (2023). Toxicity of methomyl insecticides to testicular cells and protective effect of folic acid. *Toxicology and Industrial Health*, 39(9), 481–490. <https://doi.org/10.1177/07482337221140221>
- Mahgoub, A. A., & El-Medany, A. H. (2001). Evaluation of chronic exposure of the male rat reproductive system to the insecticide methomyl. *Pharmacological Research*, 44(2), 73–80. <https://doi.org/10.1006/phrs.2001.0816>
- Meng, S., Chen, X., Song, C., Fan, L., Qiu, L., Zheng, Y., Chen, J., & Xu, P. (2021). Effect of chronic exposure to pesticide methomyl on antioxidant defense system in testis of tilapia (*Oreochromis niloticus*) and its recovery pattern. *Applied Sciences*, 11(8), 3332. <https://doi.org/10.3390/app11083332>
- Meng, S. L., Qiu, L. P., Hu, G. D., Fan, L. M., Song, C., Zheng, Y., Wu, W., Qu, J. H.,



- Li, D. D., & Chen, J. Z. (2016). Responses and recovery pattern of sex steroid hormones in testis of Nile tilapia (*Oreochromis niloticus*) exposed to sublethal concentration of methomyl. *Ecotoxicology*, 25, 1805–1811. <https://doi.org/10.1007/s10646-016-1726-7>
- Moghaddam, A. H., Eslami, A., Khanjani Jelodar, S., Ranjbar, M., & Hasantabar, V. (2023). Preventive effect of quercetin-Loaded nanophytosome against autistic-like damage in maternal separation model: The possible role of Caspase-3, Bax/Bcl-2 and Nrf2. *Behavioural Brain Research*, 441, 114300. <https://doi.org/10.1016/j.bbr.2023.114300>
- Mohamed, M. Z., Morsy, M. A., Mohamed, H. H., & Hafez, H. M. (2020). Paeonol protects against testicular ischaemia-reperfusion injury in rats through inhibition of oxidative stress and inflammation. *Andrologia*, 52(6), e13599. <https://doi.org/10.1111/and.13599>
- Mowafy, L., Abdel-Baki, A.-A. S., Abdel-Tawab, H., Al-Quraishy, S., Moustafa, N., Zaky, M. Y., Asran, A.-M. A., & Abdul-Hamid, M. (2024). Assessment of molluscicidal activity of *Syzygium aromaticum* essential oil against *Eobania vermiculata* under laboratory and field conditions. *Toxicon*, 108217. <https://doi.org/10.1016/j.toxicon.2024.108217>
- Navarro-Yepes, J., Zavala-Flores, L., Anandhan, A., Wang, F., Skotak, M., Chandra, N., Li, M., Pappa, A., Martinez-Fong, D., & Del Razo, L. M. (2014). Antioxidant gene therapy against neuronal cell death. *Pharmacology & Therapeutics*, 142(2), 206–230. <https://doi.org/10.1016/j.pharmthera.2013.12.007>
- Nna, V. U., Ujah, G. A., Mohamed, M., Etim, K. B., Igba, B. O., Augustine, E. R., & Osim, E. E. (2017). Cadmium chloride–induced testicular toxicity in male wistar rats; prophylactic effect of quercetin, and assessment of testicular recovery following cadmium chloride withdrawal. *Biomedicine & Pharmacotherapy*, 94, 109–123. <https://doi.org/10.1016/j.biopha.2017.07.087>
- Okur, M. H., Arslan, S., Aydogdu, B., Zeytun, H., Basuguy, E., Arslan, M. S., Ibiloglu, I., & Kaplan, I. (2018). Protective effect of cordycepin on experimental testicular ischemia/reperfusion injury in rats. *Journal of Investigative Surgery*, 31(1), 1–8.
- Olla, S., Siguri, C., Fais, A., Era, B., Fantini, M. C., & Di Petrillo, A. (2023). Inhibitory effect of quercetin on oxidative endogen enzymes: A focus on putative binding modes. *International Journal of Molecular Sciences*, 24(20), 15391. <https://doi.org/10.3390/ijms242015391>
- Ommati, M., Zamiri, M., Akhlaghi, A., Atashi, H., Jafarzadeh, M., Rezvani, M., & Saemi, F. (2013). Seminal characteristics, sperm fatty acids, and blood biochemical attributes in breeder roosters orally administered with sage (*Salvia officinalis*) extract. *Animal Production Science*, 53(6), 548–554. <https://doi.org/10.1071/AN12257>
- Prakash, L., & David, M. (2022). Carbosulfan Induced Reproductive Toxicity in Male Albino Rats (*Rattus norvegicus*) and Protective effect of *Cissus quadrangularis*. *Toxicology International*, 29(1), 133–145. <https://doi.org/10.18311/ti/2022/v29i1/28635>
- Radad, K., Hashim, A., El-Sharqawy, E. G., & Youssef, M. (2009). Histopathological effects of methomyl on Sprague-Dawley rats after repeated application. *Bulgarian Journal of Veterinary Medicine*, 12(2).
- Saha, S., Buttari, B., Profumo, E., Tucci, P., & Saso, L. (2022). A perspective on Nrf2 signaling pathway for neuroinflammation: A potential

- therapeutic target in Alzheimer's and Parkinson's diseases. *Frontiers in Cellular Neuroscience*, 15, 787258. <https://doi.org/10.3389/fncel.2021.787258>
- Sakr, S., Hassanien, H., Bester, M. J., Arbi, S., Sobhy, A., El Negrish, H., & Steenkamp, V. (2018). Beneficial effects of folic acid on the kidneys and testes of adult albino rats after exposure to methomyl. *Toxicology Research*, 7(3), 480–491. <https://doi.org/10.1039/c7tx00309a>
- Seleem, A. A. (2019). Induction of hyperpigmentation and heat shock protein 70 response to the toxicity of methomyl insecticide during the organ development of the Arabian toad, *Bufo arabicus* (Heyden, 1827). *Journal of Histotechnology*, 42(3), 104–115. <https://doi.org/10.1080/01478885.2019.1619653>
- Selvam, A., Gnana, D., Thatheyu, A., & Vidhya, R. (2013). Biodegradation of the synthetic pyrethroid, fenvalerate by *Bacillus cereus* Mtcc 1305. *World Journal of Environmental Engineering*, 1(2), 21–26. <https://doi.org/10.12691/ajmr-1-2-4>
- Shah, P. M., Priya, V. V., & Gayathri, R. (2016). Quercetin-a flavonoid: a systematic review. *Journal of Pharmaceutical Sciences and Research*, 8(8), 878-888.
- Shalaby, M., El Zorba, H., & Ziada, R. M. (2010). Reproductive toxicity of methomyl insecticide in male rats and protective effect of folic acid. *Food and Chemical Toxicology*, 48(11), 3221–3226. <https://doi.org/10.1016/j.fct.2010.08.027>
- Taheri, S., Karaca, Z., Mehmetbeyoglu, E., Hamurcu, Z., Yilmaz, Z., Dal, F., Çınar, V., Ulutabanca, H., Tanriverdi, F., & Unluhizarci, K. (2022). The role of apoptosis and autophagy in the hypothalamic-pituitary-adrenal (HPA) axis after traumatic brain injury (TBI). *International Journal of Molecular Sciences*, 23(24), 15699. <https://doi.org/10.3390/ijms232415699>
- Tsukamura, H. (2022). Kobayashi Award 2019: The neuroendocrine regulation of the mammalian reproduction. *General and Comparative Endocrinology*, 315, 113755. <https://doi.org/10.1016/j.ygcen.2021.113755>
- Tvrda, E., Kováč, J., Ferenczyová, K., Kaločayová, B., Ďuračka, M., Benko, F., Almášiová, V., & Barteková, M. (2022). Quercetin ameliorates testicular damage in Zucker diabetic fatty rats through its antioxidant, anti-inflammatory and anti-apoptotic properties. *International Journal of Molecular Sciences*, 23(24), 16056. <https://doi.org/10.3390/ijms232416056>
- Uylaş, M. U., Şahin, A., Şahintürk, V., & Alataş, İ. Ö. (2018). Quercetin dose affects the fate of hepatic ischemia and reperfusion injury in rats: Experimental research. *International Journal of Surgery*, 53, 117–121. <https://doi.org/10.1016/j.ijsu.2018.03.043>
- van den Boogaard, W. M., Komninos, D. S., & Vermeij, W. P. (2022). Chemotherapy side-effects: Not all DNA damage is equal. *Cancers*, 14(3), 627. <https://doi.org/10.3390/cancers14030627>
- Van Scoy, A. R., Yue, M., Deng, X., & Tjeerdema, R. S. (2013). Environmental fate and toxicology of methomyl. In D. M. Whitacre (Ed.), *Reviews of Environmental Contamination and Toxicology* (Vol. 227, pp. 93-109). Springer.
- Xu, J., Li, Y., Yang, X., Li, H., Xiao, X., You, J., Li, H., Zheng, L., Yi, C., & Li, Z. (2024). Quercetin inhibited LPS-induced cytokine storm by interacting with the AKT1-FoxO1 and Keap1-Nrf2 signaling pathway in macrophages. *Scientific Reports*, 14(1), 20913. <https://doi.org/10.1038/s41598-024-71569-y>

- Yang, D., Wang, T., Long, M., & Li, P. (2020). Quercetin: Its main pharmacological activity and potential application in clinical medicine. *Oxidative Medicine and Cellular Longevity*, 2020(1), 8825387. <https://doi.org/10.1155/2020/8825387>
- Ye, X., & Liu, J. (2019). Effects of pyrethroid insecticides on hypothalamic-pituitary-gonadal axis: a reproductive health perspective. *Environmental Pollution*, 245, 590–599. <https://doi.org/10.1016/j.envpol.2018.11.031>
- Yu, W., Zhu, H., Huang, R., Yan, B., Xu, B., Shi, Y., Mao, J., Liu, Z., & Wang, J. (2024). Roles of cyt-c/caspase-9/caspase-3/bax/bcl-2 pathway in cd-induced testicular injury in rats and the protective effect of quercetin. *Toxicon*, 237, 107561. <https://doi.org/10.1016/j.toxicon.2023.107561>
- Zhou, Y., Qian, C., Tang, Y., Song, M., Zhang, T., Dong, G., Zheng, W., Yang, C., Zhong, C., & Wang, A. (2023). Advance in the pharmacological effects of quercetin in modulating oxidative stress and inflammation related disorders. *Phytotherapy Research*, 37(11), 4999-5016. <https://doi.org/10.1002/ptr.7966>